ORAL AND MAXILLOFACIAL IMPLANTS

Ultrasonic osteotomy in oral surgery and implantology

Alberto González-García, DDS,[a] Márcio Diniz-Freitas, DDS, PhD,[a]
Manuel Somoza-Martín, DDS, PhD,[a] and Abel García-García, MD, PhD,[b]
Santiago de Compostela, Spain
UNIVERSITY OF SANTIAGO DE COMPOSTELA

Over the past decade, coinciding with the appearance of a number of new ultrasonic surgical devices, there has been a marked increase in interest in the use of ultrasound in oral surgery and implantology. This paper reviews the published literature on ultrasonic osteotomy in this context, summarizes its advantages and disadvantages, and suggests when it may and may not be the technique of choice. **(Oral Surg Oral Med Oral Pathol Oral Radiol Endod 2009;108:360-367)**

The use of ultrasound for medical diagnosis was first investigated in the 1940s and 1950s and became well established in the 1960s. The possibility of surgical applications was also explored in the 1940s,[1] but wide clinical use in Western nations was for a long period limited to dental practice, where it continues to be used for supra- and infragingival dental cleaning, and root scaling,[2-4] for apical box preparation prior to regrograde filling,[5] for root canal preparation,[3] and for the removal of posts, cores, and occasionally broken instruments.[4,6] The 1980s and 1990s saw the growing clinical introduction of both focused ultrasound[7-9] and the ultrasonic scalpel.[10-12] Ultrasonic osteotomy preparation was studied following earlier works,[13,14] but it is only in the last few years that ultrasonic devices for osteotomy have become competitive with conventional instruments in certain contexts.[15-19] To our knowledge, ultrasonic osteotomes are currently manufactured by Mectron (Genova, Italy), BTI (Vitoria, Spain), Resista (Omegna, Italy), Satelec (Merignac, France), Electro Medical Systems (Nyon, Switzerland), and NSK (Kanuma, Japan); other companies are on the verge of entering the market.

This paper reviews the published literature on ultrasonic osteotomy in oral surgery and implantology, summarizes its advantages and disadvantages, and suggests when it may be the technique of choice and when not.

[a]Assistant Professor, Departments of Oral Surgery and Oral Medicine.
[b]Head of Section, Department of Maxillofacial Surgery, Clinical University Hospital.
Received for publication Oct 3, 2008; returned for revision Apr 1, 2009; accepted for publication Apr 13, 2009.
1079-2104/$ - see front matter

doi:10.1016/j.tripleo.2009.04.018

This review is based on a search of the main on-line medical databases for papers on ultrasonic bone surgery published in major oral surgery, periodontal and dental implant journals between January 1960 and August 2008, using the keywords "piezoelectric," "ultrasonic," "bone," and "surgery." Other relevant papers were identified in the references sections of papers retrieved by the primary search. It should be pointed out that ≥1 of the authors of a number of the papers reviewed appear to have a commercial interest in the osteotomes used in their studies.

BASIC CONCEPTS

Ultrasound consists of mechanical waves of frequencies greater than about 20 kHz, the upper limit of human hearing. Although vibrations of these frequencies can be produced by various means, most medical devices currently use the piezoelectric effect, discovered in 1880 by Jacques and Pierre Curie.[20] This is the phenomenon whereby an electric potential develops across certain crystalline materials when they are compressed; and these materials become deformed in an electric field. If the polarity of the applied field alternates, the crystal transduces this alternation into an oscillation of its surface, and this movement is transmitted to adjacent matter.

Ultrasonic medical devices generally use barium titanate transducers. In ultrasonic scalpels and osteotomes they are located in the handpiece, which is connected by a cable to the control unit. Their movement is transmitted to a working piece that is inserted in the handpiece and has a titanium or steel tip, with or without a diamond or titanium nitride coating, that is shaped appropriately for the intended task (Fig. 1). To cut bone while minimizing the risk of damage to soft tissues, osteotomes use ultrasound of relatively low

Fig. 1. Various designs of ultrasonic osteotomy tip.

frequencies (20-36 kHz) which in some cases may optionally be modulated at low frequency (30 Hz or lower) to avoid overheating and bone compaction.[21] The instantaneous frequency is generally automatically controlled in response to the pressure load on the tip. The parameters under the control of the operator, apart from the pressure applied, are the pulse frequency (when available), the rate of delivery of coolant fluid, and the applied power, which in some instruments is limited to 3-16 W and in others has a maximum of as much as 90 W.[22] In most instruments, power is controlled by selecting the type of bone to be cut or the procedure to be performed. The peak-to-peak amplitude of tip oscillations, typically in the range of 30-200 μm in the plane perpendicular to the shaft of the working piece (some instruments also or exclusively[23,24] oscillate along the shaft), ensures precise microabrasive incision. Cavitation (the production of imploding bubbles,[25] a phenomenon to be avoided in many applications of ultrasound in the presence of liquids) apparently occurs advantageously in ultrasonic osteotomy, in which it helps maintain good visibility in the surgical field by dispersing coolant fluid as an aerosol.

It must be stressed that ultrasonic osteotomy and conventional osteotomy demand quite different manual controls of the operator. Whereas exerting more pressure on a rotary bur accelerates incision, placing excessive pressure on an ultrasonic tip can prevent its proper vibration, and experience with endodontic ultrasound suggests with this will result in overheating.[26] At each moment, a pressure must be used that is right for the bone being cut. Although the use of appropriate pressure minimizes the risk of overheating, regular interruptions to prevent overheating are nevertheless advisable, especially during long or deep cuts.[27]

Table I. Papers on clinical applications of ultrasonic osteotomy in oral surgery and implantology, by year of publication within each surgery type

Sinus lift	
Torrella et al.[15]	1998
Vercellotti et al.[28]	2001
Eggers et al.[29]	2004
Stübinger et al.[16]	2005
Vercellotti et al.[30]	2006
Schlee et al.[31]	2006
Wallace et al.[32]	2007
Stübinger et al.[33]	2008
Barone et al.[34]	2008*
Blus et al.[35]	2008
Alveolar ridge expansion	
Vercellotti[30]	2000
Blus & Szmukler-Moncler[31]	2006
Schlee et al.[26]	2006
Eisnidis et al.[37]	2006
Stübinger et al.[28]	2008
Exposure of impacted canines	
Grenga and Bovi[38]	2004
Lateralization of the inferior alveolar nerve (IAN)	
Bovi[39]	2005
Stübinger et al.[16]	2005
Leclercq et al.[40]	2008
Stübinger et al.[33]	2008
Removal of hard tissue close to the IAN	
Stübinger et al.[16]	2005
Autologous bone graft harvesting	
Stübinger et al.[16]	2005
Stübinger et al.[45]	2006
Schlee et al.[31]	2006
Happe A.[46]	2007
Sohn et al.[47]	2007
Gellrich et al.[48]	2007
Leclercq et al.[40]	2008
Stübinger et al.[33]	2008
Periodontal surgery	
Vercellotti et al.[30]	2006
Transposition of the IAN	
Sakkas et al.[49]	2008
Alveolar distraction osteogenesis	
González-García et al.[50]	2007
Lee et al.[51]	2007
González-García et al.[52]	2008*
Removal of osseointegrated implants	
Silovella et al.[53]	2007
Leclercq et al.[40]	2008

*In vivo comparative study of control and test groups.

SEARCH RESULTS

Clinical experience in oral surgery and implantology

The literature search showed ultrasonic osteotomy to have been used to date in the following orosurgical and implantological procedures: sinus lift,[15,16,28-35] alveolar ridge expansion,[22,31,33,36,37] exposure of impacted canines,[38] lateralization of the inferior alveolar nerve

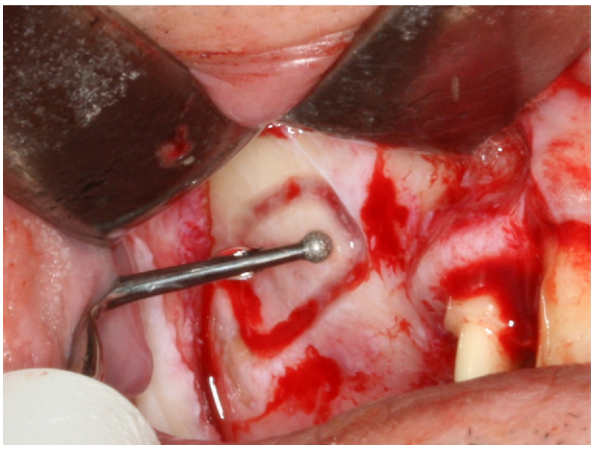

Fig. 2. Ultrasonic osteotomy of the maxilla in a sinus lift procedure.

(IAN),[33,39,40] removal of osseous tissue close to the IAN,[16] orthognathic surgery,[41-44] autologous bone graft harvesting,[16,31,33,45-48] periodontal surgery,[30] IAN transposition,[49] alveolar distraction osteogenesis,[50-52] and the removal of osseointegrated implants[40,53] (Table I). The results reported are reviewed in the following subsections.

Sinus lift (Fig. 2). Sinus lift is the procedure for which the use of ultrasonic osteotomy was first reported,[15] and for which most reports of its use have been published.[16,28-35] The most common intraoperative complication of conventionally performed sinus lift is perforation of the schneiderian membrane, which occurs in 14%-56%[32] of cases (generally due to accidental slipping of the osteotome) and can cause postoperative complications such as infection.[54-56] In noncomparative observational studies, Vercellotti et al.[28] reported a perforation rate of only 1 out of 21 (4.8%), Blus et al.[35] reported a perforation rate of only 2 out of 53 membranes (3.8%), and there were no perforations at all during actual bone cutting in the series of 100 cases described by Wallace et al.[32] These low rates are attributed to the use of ultrasound frequencies of only 25-30 kHz, lower than those that cut soft tissue (ultrasonic scalpels use frequencies of ~55 kHz)[12]; even contact between osteotome and soft tissue due to accidental slipping may inflict no incisive damage. However, in a split-mouth study of 26 sinus lifts randomly assigned to execution with ultrasonic and rotary instruments, Barone et al.[34] perforated the schneiderian membrane more frequently with the ultrasonic osteotome (4 vs. 3 times), though the difference was not statistically significant.

Other aspects of ultrasonic osteotomy that have been noted in papers on sinus lift include the advantages of improved visibility and the possibility of more conservative cuts,[15] and the disadvantage that the procedure was lengthier with the ultrasonic osteotome than with conventional instruments,[34] though again the difference was not statistically significant.

Alveolar ridge expansion. Vercellotti[36] reported that ultrasonic osteotomy allowed single-session alveolar ridge expansion and implant placement, and that implants could be placed in previously inaccessible locations. Blus and Szmukler-Moncler,[22] who used both Mectron and Resista osteotomes, placed 228 of 230 planned implants in 57 patients, with a successful osseointegration rate of 220 out of 228 (96.5%) at second-stage surgery and no failures among osseointegrated implants after follow-up times of up to 36 months (median ~10 months); although no statistical analyses were performed to support comparisons, these authors reported that ultrasonic ridge expansion technique was learned more quickly than conventional techniques, and that the Resista osteotome was more efficient than the Mectron instrument, especially in type IV bone, because of its wider frequency range and greater power. Enislidis et al.[37] presented a new approach to ridge splitting in the mandible. It is based on surgery in 2 steps, with a delay of ~40 days between them and using the ultrasonic osteotomy at first, with good results. Finally, Stübinger et al.[33] described ultrasonic ridge splitting as easier and safer than conventional methods, but also as more time consuming.

IAN positioning and vulnerability. Ultrasonic osteotomy was first used to reposition the IAN in 2005, by Bovi,[39] whose case report mentions better surgical approach, lower risk of damage to the nerve, and the reduction of mental nerve stretching through the use of a smaller window and apicocoronal instrument inclination to capture the neurovascular bundle, a method that is impossible with conventional instruments. In subsequent case series,[33,40,49] ultrasonic osteotomy has been described as minimally harmful in IAN lateralization and transposition, which was referred to as one of the major indications for this technology.

Orthognathic surgery. Geha et al.[41] reported that IAN integrity was respected in 20 bilateral mandibular sagittal split operations, with 75%-80% recovery of neurosensory function within 2 months. Landes et al.[42] reported that, at 3-month follow-up, IAN sensation was retained in 95% of 50 patients who underwent predominantly ultrasonic orthognathic surgery acompared with 85% of 86 for whom wholly conventional techniques were used ($P = .0003$), with less intraoperative blood loss ($P = .001$) and no significant increase in operation time. Others have reported 2-month sensory normalization rates of 43%[43] and 82%.[44] Landes et al.[42] stressed that the precision of ultrasonic osteotomy should allow the design of osteotomies that maintain

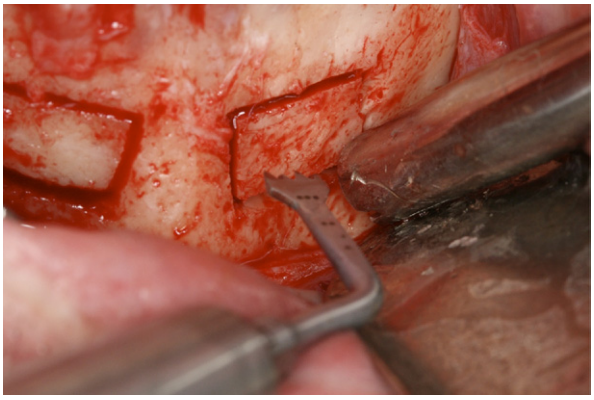

Fig. 3. Ultrasonic osteotomy of the mandible in a bone-harvesting procedure.

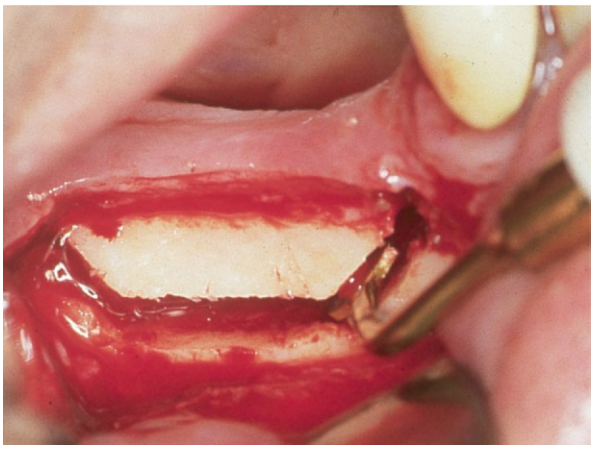

Fig. 4. Ultrasonic osteotomy of the mandible in an alveolar distraction osteogenesis procedure.

bone contact or interdigitation after repositioning, thus minimizing the need for osteofixation.

Bone harvesting (Fig. 3). Stübinger et al.[16] reported excellent postoperative healing of ultrasonically harvested canine eminence bone used for sinus lift, but also noted the need for a longer operation time. Good average graft size and healing were also observed in a series of 40 cases of ultrasonic bone harvesting from the mandibular ramus.[46] Other reported advantages of ultrasonic bone harvesting include better access and surgical control, with the consequent avoidance of hammer blows and reduction of fracture risk,[40] a cutting geometry that is more versatile and precise than in conventional methods,[33] and less vibration and noise, with consequent minimization of psychologic stress to the patient.[47] Although in most bone grafts for implant preparation the need for general anesthesia is avoided by harvesting bone intraorally, from the chin bone and the upper mandibular ramus, ultrasonic osteotomy has recently been used to harvest from the zygomatic-maxillary region, which because of appropriate bone shape is advantageous for anterior maxillary implant preparation.[45,48]

Alveolar distraction osteogenesis (Fig. 4). As in the applications discussed above, the use of ultrasonic osteotomy in both mandibular[50] and maxillary[51] alveolar distraction osteogenesis has been reported to allow precise osteotomy with excellent surgical visibility and low risk to soft tissue, including the IAN and lingual periosteum. However, although a recent small comparative study[52] confirmed that the surgical complexity of ultrasonic osteotomy (6 patients) was less than that of conventional procedures (11 patients) and that the incidence of intraoperative complications was lower, it also found that the postdistraction morphology of the alveolar ridge at implant placement was worse in the ultrasonic group, and that the overall rehabilitation success rate was only 66.7% compared with 100% among conventionally treated patients.

Others. Cases have been reported in which ultrasonic osteotomy has been used successfully for impacted canine exposure,[38] the removal of tissue in the vicinity of the IAN,[16] periodontal surgery,[30] and the removal of osseointegrated implants.[40,53]

Other relevant surgical reports

Doubtless due to the already well established use of ultrasound for periodontal scaling, ultrasonic osteotomy has been most extensively tested in the fields of oral surgery and implantology on which this review centers. However, reports on its incipient application in other surgical areas are also relevant to its evaluation for oral surgery. For example, Hoigne et al.[18] found that it allowed highly precise incision of metacarpal bone, with good healing and no neurovascular involvement, and although operation time was slightly longer than with an oscillating saw, the possibility of curved cutting constituted a distinct advantage over the latter. Similar results have been obtained in otologic surgery[19] and in cranial and spinal surgery,[17,29,57,58] where it avoided damage to the dura mater and, because of its precision, allowed novel bone manipulation procedures with overall saving in surgical time.

Experimental studies

Several authors have published the results of experimental studies carried out in preparation for the clinical trial of ultrasonic osteotomy. For example, Kotrikova et al.[17] found that in experiments with bovine long bone an ultrasonic osteotome not only cut compact cortical bone 5 times slower than a Lindemann bur (though faster than an oscillating saw), but also caused a greater

Table II. Main advantages and disadvantages of ultrasonic osteotomy

Advantages
Minimal risk to soft tissue, which vibrates without fracture in contact with the osteotome tip.
Excellent visibility within the surgical field, due in part to minimal bleeding and in part to the cavitation effect, which converts the irrigation solution into an aerosol and removes osteotomic detritus.
Precise cutting thanks to limited vibration amplitude (max. 200 μm) and the design of osteotome tips for specific surgical situations and tasks.
Geometric cutting. Possibility of curved cuts.
Low acoustic and vibration impact on patient.
Disadvantages
Slowness. Cutting very dense bone with ultrasound can take up to 4 times longer than with a rotary bur.
Tip breakage. The frequency of tip breakage makes it necessary to maintain a stock of tips.
Higher cost. Ultrasonic osteotomy equipment is currently more expensive than mechanical osteotomes.

increase in temperature, 8.2°C compared with 3.9°C (1.8°C with the oscillating saw), although no coagulation necrosis was observed during subsequent clinical application. Regarding the need for presurgical training, Khambay and Walmsley[23,24] reported that an ultrasonic chisel required more time and less applied force to cut fresh bovine femur than did a rotary bur. In experiments on IAN repositioning using dead sheep jaws, Metzger et al.[59] found that affected bone surfaces were less smooth with an ultrasonic osteotome than with a rotary diamond bur, that bone particles were more numerous and defects deeper (150 μm compared with 50 μm), and that epineurium lesions also occurred, although deeper structures were not affected if the IAN was touched; it was concluded that the ultrasonic technique was more invasive to bone but less risky for the nerve. In contrast, Sun et al.[60] observed no microcracks around the edge of an incision made in an anesthetized dog's rib and Maurer et al.[61] reported that, unlike conventional osteotomy, ultrasound preserved the visible distinction between cortical and cancellous rabbit skull bone, and that the roughness of ultrasonically osteotomized bone surface was significantly less than that of bur-osteotomized surface.

Several published experimental studies have examined the consequences of ultrasound for subsequent bone regeneration. Sura et al.[62] reported that cultures of osteoblasts from rat parietal cortex exhibited diminished viability for at least 20 hours after exposure to ultrasound. However, Chiriac et al.[63] found that ultrasonically obtained cortical bone chips were larger than chips obtained with rotary burs and did not differ significantly from the conventionally obtained chips regarding the time required for cell proliferation and the differentiation of osteoblasts; and Vercellotti et al.[64] reported that in periodontal resection experiments on dogs, bone had increased 8 weeks after ostectomy/osteoplasty with ultrasound, but had decreased if carbide or diamond burs had been used. At a more basic level, Perfetti et al.[65] observed that, 30 minutes after surgery, bone obtained by ultrasonic osteotomy had a lower alkaline phosphatase level than bone obtained by rotary drilling; and Preti et al.[66] found that bone around titanium implants set in minipig tibias exhibited fewer inflammatory cells, lower proinflammatory cytokine levels, an earlier increase in bone morphogenetic protein 4 and transforming growth factor β2, and more active neo-osteogenesis 7 weeks after surgery if the bone had been prepared by ultrasonic osteotomy than if conventional drilling had been used. Finally, Kerr et al.[67] recently reported that ultrasound treatment (10 20 minute sessions over 4 weeks) had no significant influence on alveolar bone loss after tooth extraction.

DISCUSSION

Reported specific advantages and disadvantages of ultrasonic osteotomy (Table II)

Advantages. The primary advantage of ultrasonic osteotomy, mentioned repeatedly by numerous authors, is the low associated risk to adjacent soft tissues, notably the IAN, the periosteum, the schneiderian membrane, and oral mucosa. Secondly, surgical accuracy is facilitated by good visibility in the surgical field,[15,43,46,50] which is a consequence of both decreased bleeding[42] and the evacuation of detritus by the coolant solution being optimized by the cavitation effect. Thirdly, ultrasonic cuts have been reported to be more precise[21,57] and to cause less splintering at the margin of the incision,[18,47] both of which advantages derive not only from the ultrasonic cutting mechanism per se, which avoids the "macrovibrations" associated with the use of rotary instruments, but also from the small tip size and ample choice of tip shape that it allows; this advantage may be especially prominent in precision procedures performed with the aid of optical magnification. Fourthly, the ultrasonic osteotome allows curved cuts that are impossible with rotary or oscillating saws[18]; this advantage may be especially of interest in bone surgeries where a particular geometric design of the osteotomy is required. Finally, the ultrasonic osteotome produces

much less noise and subjective sensation of vibration than do rotary instruments, which reduces the psychologic stress on patients under local anesthesia.[47]

Disadvantages. The main disadvantage of ultrasonic osteotomy that is mentioned by a number of authors is its slow cutting rate,[17,23,29] or equivalently its poor efficiency,[40] at least compared with conventional osteotomy: Cutting times up to 3 or 4 times longer have been reported for some oral procedures.[44] Although cutting time tends to decrease as the operator gains experience,[44] this slowness—partly due to the need to pause to allow cooling—can be particularly striking in the case of the dense cortical bone that is cut in procedures such as bone graft harvesting, alveolar distraction osteogenesis, and alveolar ridge expansion.[28,29] It has been recommended that for deep cuts it is preferable for initial incision with ultrasound to be followed by the use of a manual chisel.[29] However, other authors have noted no such increase in cutting time,[42] and total surgical times are either not so much longer as to pose a serious problem or are actually shorter because of less time-consuming pre- or postosteotomy procedures.[44,58] Moreover, cutting efficiency can be increased by applying more ultrasound power, if available, although there is a trade-off between cutting efficiency and the risk of thermal bone damage that must be taken into account in the adjustment of operating technique.[22] Perhaps the main point to be aware of regarding cutting efficiency is that the harder the bone, the greater the likelihood that the osteotome tip will break; care must therefore be taken to maintain a sufficient stock of tips.

Some authors have regarded it to be a disadvantage of ultrasonic osteotomy that the required operating technique differs from that of conventional osteotomy, and that its acquisition may take some time,[24,44] although opinions differ.[27] However, it has also been reported that it takes considerably less time to master the ultrasonic osteotome than the rotary saw or manual chisel.[22]

Apart from the above possible disadvantages, ultrasonic osteotomy also, of course, shares with ultrasonic scaling a number of possible complications and adverse side effects that must be borne in mind, including the possibility of intravascular thrombosis and surface coagulation due to heat.[68-72] The risk of these effects may be greater in the case of ultrasonic osteotomy because of its greater power requirements, especially when it is applied to poorly vascularized bone such as jaw.

CONCLUSION

The intraoperative advantages of ultrasonic osteotomy seem to be well established: visibility of the surgical field, precise control of cuts, and, above all, low risk to adjacent soft tissue. However, its poor capacity to cut dense bone is also well established, and its performance regarding postoperative bone regeneration is still unclear and will require further evaluation in appropriately sized studies. Although experimental in vitro and in vivo studies have mainly suggested that bone regeneration after ultrasonic osteotomy is no worse than after conventional osteotomy, experience of its use in alveolar distraction osteogenesis has been disappointing. At present, it therefore seems wise for decisions on whether to use ultrasonic or conventional osteotomy to be based on the principle of minimizing the risk of the most likely serious complications, as follows.

Where there is a significant risk of damage to nerves or other soft tissues of major importance, and bone cuts are to be relatively shallow, ultrasonic osteotomy may be the technique of choice. Indeed, it may prove to be of greatest value for surgery of the cranium, neck, and spine rather than oral surgery. Risk is of course increased when a surgeon must undertake a procedure of which he or she has little experience.

Where soft tissue damage is less likely, or less likely to constitute a severe complication, and where the osseous postsurgical neoformation is decisive at the osteotomy site for the success of the surgery, it may be more desirable for a professional with sufficient expertise to guard against bone regeneration failure by using a conventional technique.

Finally, it should be borne in mind that the combined sequential use of ultrasonic and conventional techniques may be more effective overall than any one approach by itself, as has already been found in some of the case reports in the literature reviewed.

REFERENCES

1. Lynn JG, Zwemer RL, Chick AJ, The biological application of focused ultrasonic waves. Science 1942;96:119-20.
2. Walmsley AD. Ultrasonic and sonic scalers. Br Dent Surg Assist 1989;48:26-8.
3. Walmsley AD, Laird WR, Lumley PJ. Ultrasound in dentistry part 2—periodontology and endodontics. J Dent 1992;20:11-7.
4. Smith BJ. Removal of fractured posts using ultrasonic vibration: an in vivo study. J Endod 2001;27:632-4.
5. Peñarrocha M, Martí E, García B, Gay C. Relationship of periapical lesion radiologic size, apical resection, and retrograde filling with the prognosis of periapical surgery. J Oral Maxillofac Surg 2007;65:1526-9.
6. Ward JR, Parashos P, Messer HH. Evaluation of an ultrasonic technique to remove fractured rotary nickel-titanium endodontic instruments from root canals: an experimental study. J Endod 2003;29:756-63.
7. Mulligan ED, Lynch TH, Mulvin D, Greene D, Smith JM, Fitzpatrick JM. High-intensity focused ultrasound in the treatment of benign prostatic hyperplasia. Br J Urol 1997;79:177-80.
8. Chapelon JY, Ribault M, Vernier F, Souchon R, Gelet A. Treatment of localised prostate cancer with transrectal high intensity focused ultrasound. Eur J Ultrasound 1999;9:31-8.

9. Kennedy JE, Ter Haar GR, Cranston D. High intensity focused ultrasound: surgery of the future? Br J Radiol 2003;76:590-9.
10. Shelley ED, Shelley WB. Piezosurgery: a conservative approach to encapsulated skin lesions. Cutis 1986;38:123-6.
11. Lee SJ, Park KH. Ultrasonic energy in endoscopic surgery. Yonsei Med J 1999;40:545-9.
12. Sherman JA, Davies HT. Ultracision: the harmonic scalpel and its possible uses in maxillofacial surgery. Br J Oral Maxillofac Surg 2000;38:530-2.
13. Horton JE, Tarpley TM Jr, Wood LD. The healing of surgical defects in alveolar bone produced with ultrasonic instrumentation, chisel, and rotary bur. Oral Surg Oral Med Oral Pathol Oral Radiol Endod 1975;39:536-46.
14. Horton JE, Tarpley TM Jr, Jacoway JR. Clinical applications of ultrasonic instrumentation in the surgical removal of bone. Oral Surg Oral Med Oral Pathol Oral Radiol Endod 1981;51:236-42.
15. Torrella F, Pitarch J, Cabanes G, Anitua E. Ultrasonic ostectomy for the surgical approach of the maxillary sinus: a technical note. Int J Oral Maxillofac Impants 1998;13:697-700.
16. Stübinger S, Kuttenberger J, Filippi A, Sader R, Zeilhofer HF. Intraoral piezosurgery: preliminary results of a new technique. J Oral Maxillofac Surg 2005;63:1283-7.
17. Kotrikova B, Wirtz R, Krempien R, Blank J, Eggers G, Samiotis A, Mühling J. Piezosurgery—a new safe technique in cranial osteoplasty? Int J Oral Maxillofac Surg 2006;35:461-5.
18. Hoigne DJ, Stübinger S, Von Kaenel O, Shamdasani S, Hasenboehler P. Piezoelectric osteotomy in hand surgery: first experiences with a new technique. BMC Musculoskelet Disord 2006;7:36.
19. Salami A, Dellepiane M, Mora F, Crippa B, Mora R. Piezosurgery in the cochleostomy through multiple middle ear approaches. Int J Pediatr Otorhinolaryngol 2008;72:653-7.
20. Curie J, Curie P. Contractions et dilatations produites par des tensions dans les cristaux hémièdres à faces inclinées. C R Acad Sci Gen 1880;93:1137-40.
21. Vercellotti T. Technological characteristics and clinical indications of piezoelectric bone surgery. Minerva Stomatol 2004;53:207-14.
22. Blus C, Szmukler-Moncler S. Split-crest and immediate implant placement with ultra-sonic bone surgery: a 3-year life-table analysis with 230 treated sites. Clin Oral Implants Res 2006;17:700-7.
23. Khambay BS, Walmsley AD. Investigations into the use of an ultrasonic chisel to cut bone. Part 2: cutting ability. J Dent 2000;28:39-44.
24. Khambay BS, Walmsley AD. Investigations into the use of an ultrasonic chisel to cut bone. Part 1: forces applied by clinicians. J Dent 2000;28:31-7.
25. Laird WR, Walmsley AD. Ultrasound in dentistry. Part 1—biophysical interactions. J Dent 1991;19:14-7.
26. Budd JC, Gekelman D, White JM. Temperature rise of the post and on the root surface during ultrasonic post removal. Int Endod J 2005;38:705-11.
27. Robiony M, Polini F, Costa F, Vercellotti T, Politi M. Piezoelectric bone cutting in multipiece maxillary osteotomies. J Oral Maxillofac Surg 2004;62:759-61.
28. Vercellotti T, de Paoli S, Nevins M. The piezoelectric bony window osteotomy and sinus membrane elevation: introduction of a new technique for simplification of the sinus augmentation procedure. J Periodontics Restor Dent 2001;21:561-7.
29. Eggers G, Klein J, Blank J, Hassfeld S. Piezosurgery: an ultrasound device for cutting bone and its use and limitations in maxillofacial surgery. Br J Oral Maxillofac Surg 2004;42:451-3.
30. Vercellotti T, Pollack AS. A new bone surgery device: sinus grafting and periodontal surgery. Compend Contin Educ Dent 2006;27:319-25.
31. Schlee M, Steigmann M, Bratu E, Garg AK. Piezosurgery: basics and possibilities. Implant Dent 2006;15:334-40.
32. Wallace SS, Mazor Z, Froum SJ, Cho SC, Tarnow DP. Schneiderian membrane perforation rate during sinus elevation using piezosurgery: clinical results of 100 consecutive cases. Int J Periodontics Restorative Dent 2007;27:413-9.
33. Stübinger S, Landes C, Seitz O, Zeilhofer HF, Sader R. [Ultrasonic bone cutting in oral surgery: a review of 60 cases]. Ultraschall Med 2008;29:66-71. German.
34. Barone A, Santini S, Marconcini S, Giacomelli L, Gherlone E, Covani U. Osteotomy and membrane elevation during the maxillary sinus augmentation procedure. A comparative study: piezoelectric device vs. conventional rotative instruments. Clin Oral Implants Res 2008;19:511-5.
35. Blus C, Szmukler-Moncler S, Salama M, Salama H, Garber D. Sinus bone grafting procedures using ultrasonic bone surgery: 5-year experience. Int J Periodontics Restorative Dent 2008; 28:221-9.
36. Vercellotti T. Piezoelectric surgery in implantology: a case report—a new piezoelectric ridge expansion technique. Int J Periodontics Restorative Dent 2000;20:358-65.
37. Enislidis G, Wittwer G, Ewers R. Preliminary report on a staged ridge splitting technique for implant placement in the mandible: a technical note. Int J Oral Maxillofac Implants 2006;21:445-9.
38. Grenga V, Bovi M. Piezoelectric surgery for exposure of palatally impacted canines. J Clin Orthod 2004;38:446-8.
39. Bovi M. Mobilization of the inferior alveolar nerve with simultaneous implant insertion: a new technique. Case report. Int J Periodontics Restorative Dent 2005;25:375-83.
40. Leclercq P, Zenati C, Dohan DM. Ultrasonic bone cut part 2: state-of-the-art specific clinical applications. J Oral Maxillofac Surg 2008;66:183-8.
41. Geha HJ, Gleizal AM, Nimeskern NJ, Beziat JL. Sensitivity of the inferior lip and chin following mandibular bilateral sagittal split osteotomy using Piezosurgery. Plast Reconstr Surg 2006;118: 1598-607.
42. Landes CA, Stübinger S, Rieger J, Williger B, Ha TK, Sader R. Critical evaluation of piezoelectric osteotomy in orthognathic surgery: operative technique, blood loss, time requirement, nerve and vessel integrity. J Oral Maxillofac Surg 2008;66:657-74.
43. Gruber RM, Kramer FJ, Merten HA, Schliephake H. Ultrasonic surgery—an alternative way in orthognathic surgery of the mandible. A pilot study. Int J Oral Maxillofac Surg 2005;34:590-3.
44. Beziat JL, Bera JC, Lavandier B, Gleizal A. Ultrasonic osteotomy as a new technique in craniomaxillofacial surgery. Int J Oral Maxillofac Surg 2007;36:493-500.
45. Stübinger S, Robertson A, Zimmerer KS, Leiggener C, Sader R, Kunz C. Piezoelectric harvesting of an autogenous bone graft from the zygomaticomaxillary region: case report. Int J Periodontics Restorative Dent 2006;26:453-7.
46. Happe A. Use of a piezoelectric surgical device to harvest bone grafts from the mandibular ramus: report of 40 cases. Int J Periodontics Restorative Dent 2007;27:241-9.
47. Sohn DS, Ahn MR, Lee WH, Yeo DS, Lim SY. Piezoelectric osteotomy for intraoral harvesting of bone blocks. Int J Periodontics Restorative Dent 2007;27:127-31.
48. Gellrich NC, Held U, Schoen R, Pailing T, Schramm A, Bormann KH. Alveolar zygomatic buttress: a new donor site for limited preimplant augmentation procedures. J Oral Maxillofac Surg 2007;65:275-80.
49. Sakkas N, Otten JE, Gutwald R, Schmelzeisen R. Transposition of the mental nerve by piezosurgery followed by postoperative neurosensory control: a case report. Br J Oral Maxillofac Surg 2008;46:270-1.
50. González-García A, Diniz-Freitas M, Somoza-Martín M, García-

García A. Piezoelectric bone surgery applied in alveolar distraction osteogenesis: a technical note. Int J Oral Maxillofac Implants 2007;22:1012-6.
51. Lee HJ, Ahn MR, Sohn DS. Piezoelectric distraction osteogenesis in the atrophic maxillary anterior area: a case report. Implant Dent 2007;16:227-34.
52. González-García A, Diniz-Freitas, Somoza-Martín M, García-García A. Piezoelectric and conventional osteotomy in alveolar distraction osteogenesis in a series of 17 patients. Int J Oral Maxillofac Implants 2008;23:891-6.
53. Sivolella S, Berengo M, Fiorot M, Mazzuchin M. Retrieval of blade implants with piezosurgery: two clinical cases. Minerva Stomatol 2007;56:53-61.
54. Khoury F. Augmentation of the sinus floor with mandibular bone block and simultaneous implantation: a 6-year clinical investigation. Int J Oral Maxillofac Implants 1999;14:557-64.
55. Martos Díaz P, Naval Gías L, Sastre Pérez J, González García R, Bances del Castillo F, Mancha de la Plata M, et al. Sinus elevation by in situ utilization of bone scrapers: technique and results. Med Oral Patol Oral Cir Bucal 2007;12:E537-41.
56. Schwartz-Arad D, Herzberg R, Dolev E. The prevalence of surgical complications of the sinus graft procedure and their impact on implant survival. J Periodontol 2004;75:511-6.
57. Schaller BJ, Gruber R, Merten HA, Kruschat T, Schliephake H, Buchfelder M, Ludwig HC. Piezoelectric bone surgery: a revolutionary technique for minimally invasive surgery in cranial base and spinal surgery? Technical note. Neurosurgery 2005;57:4.
58. Kramer FJ, Ludwig HC, Materna T, Gruber R, Merten HA, Schliephake H. Piezoelectric osteotomies in craniofacial procedures: a series of 15 pediatric patients. Technical note. J Neurosurg 2006;104:68-71.
59. Metzger MC, Bormann KH, Schoen R, Gellrich NC, Schmelzeisen R. Inferior alveolar nerve transposition—an in vitro comparison between piezosurgery and conventional bur use. J Oral Implantol 2006;32:19-25.
60. Sun D, Zhou ZY, Liu YH, Shen WZ. Development and application of ultrasonic surgical instruments. IEEE Trans Biomed Eng 1997;44:462-7.
61. Maurer P, Kriwalsky MS, Veras RB, Vogel J, Syrowatka F, Heiss C. Micromorphometrical analysis of conventional osteotomy techniques and ultrasonic osteotomy at the rabbit skull. Clin Oral Impl Res 2008;19:570-5.
62. Sura H, Shelton RM, Walmsley AD. Osteoblast viability and detachment following exposure to ultrasound in vitro. J Mater Sci Mater Med 2001;12:997-1000.
63. Chiriac G, Herten M, Schwarz F, Rothamel D, Becker J. Autogenous bone chips: influence of a new piezoelectric device (piezosurgery) on chip morphology, cell viability and differentiation. J Clin Periodontol 2005;32:994-9.
64. Vercellotti T, Nevins ML, Kim DM, Nevins M, Wada K, Schenk RK, Fiorellini JP. Osseous response following resective therapy with piezosurgery. Int J Periodontics Restorative Dent 2005; 25:543-9.
65. Perfetti G, Calderini M, Berardi D, Leoni S, Ferrante M, Spoto G. Evaluation of nonspecific tissue alkaline phosphatase on bone samples from traditional and piezoelectric osteotomy. J Biol Regul Homeost Agents 2006;20:67-72.
66. Preti G, Martinasso G, Peirone B, Navone R, Manzella C, Muzio G, et al. Cytokines and growth factors involved in the osseointegration of oral titanium implants positioned using piezoelectric bone surgery versus a drill technique: a pilot study in minipigs. J Periodontol 2007;78:716-22.
67. Kerr EN, Mealey BL, Noujeim ME, Lasho DJ, Nummikoski PV, Mellonig JT. The effect of ultrasound on bone dimensional changes following extraction: a pilot study. J Periodontol 2008;79:283-90.
68. Williams AR. Intravascular mural thrombi produced by acoustic microstreaming, Ultrasound Med Biol 1977;3:191-203.
69. Williams AR, Chater BV. Mammalian platelet damage in vitro by an ultrasonic therapeutic device. Arch Oral Biol 1980;25:175-9.
70. Walmsley AD, Laird WR, Williams AR. Intra-vascular thrombosis associated with dental ultrasound, J Oral Pathol 1987;16:256-9.
71. Kocher T, Plagmann HC. Heat propagation in dentin during instrumentation with different sonic scaler tips. Quintessence Int 1996;27:259-64.
72. Trenter SC, Walmsley AD. Ultrasonic dental scaler: associated hazards. J Clin Periodontol 2003;30:95-101.

Reprint requests:

Alberto González-García
Facultad de Medicina y Odontología
Calle Entrerríos S/N, 15782
Santiago de Compostela
Spain
gonzalezygarcia@gmail.com